

A case report of a cementless total hip replacement performed in a pelvic limb amputee after a failed surgical reduction of a traumatic coxo-femoral luxation with a toggle rod

RC Elliott,  KJ van der Wettering,  A Kitshoff 

Department of Companion Animal Studies, Faculty of Veterinary Science, Onderstepoort Veterinary Academic Hospital, University of Pretoria, South Africa

Corresponding author, email: rosselliott_2@hotmail.com

Coxo-femoral luxation is the most common luxation seen in dogs after road traffic accidents. There are multiple surgical techniques to repair the luxation. These range from a capsular reconstruction to a total hip replacement. This case report describes a total hip replacement to repair a failed toggle rod repair of a coxo-femoral luxation in a Greyhound pelvic limb amputee. The dog returned to normal activity as a household pet three months post-surgery and at the last follow-up consultation at 12 months post-surgery the dog was able to maintain an acceptable activity level as an amputee with no radiographic signs of complications.

Keywords: total hip replacement, pelvic limb amputee, coxo-femoral luxation, toggle rod, open surgical reduction

Introduction

Coxo-femoral luxation is the most common joint luxation seen in small animal practice and often occurs secondary to road traffic accidents (Jones et al. 2019; Moores 2006). Given the poly-trauma often present in cases of road traffic accidents in dogs, there is often concurrent trauma of the ipsilateral and contralateral limb (Denny 1978; Moores 2006). This often complicates the surgical management of these patients as bilateral orthopaedic procedures may be required. These dogs often require supportive nursing care in the immediate postoperative period to aid in recovery.

In dogs with marked soft tissue, neurovascular and orthopaedic trauma, amputation may be the best option. Little is published on the management of contralateral orthopaedic conditions of the remaining limbs in amputees (Contreras et al. 2018). It has been documented that amputees have gait abnormalities, alterations in the centre of gravity, changes in joint range of motion of the joints and stance and stride length in the remaining limb (Contreras et al. 2018). The effects of these changes in gait are unknown on long-term joint morbidity of the remaining limbs.

Total hip replacement (THR) is reported to have excellent outcomes, in terms of subjective owner and veterinary assessments in 92–98% of dogs undergoing the procedure (Forster et al. 2012; Marino et al. 2012). Recent force plate data shows that the ground reaction forces in pelvic limbs that have undergone THR are similar to ground reaction forces in the contralateral normal pelvic limb (Kalis et al. 2012; Liska 2010). In comparison, a study looking at kinematic gait assessment in patients where a femur head and neck resection was performed showed that 38% of patients had a favourable outcome based on gait assessment (Matis 2010). Currently, the most common indication for THR is the management of hip dysplasia with secondary osteoarthritis and non-responsive pain. There are numerous reports of the use of THR in traumatic injuries to the coxo-femoral joint (Jones et al. 2019; Liska 2010; Marino et

al. 2012). The use of THR for recurrent or chronic coxo-femoral luxation has shown excellent outcomes (Jones et al. 2019).

There are two reports of THR being performed in pelvic limb amputees in the literature. The first of these made use of a cemented THR system with a complication rate of 56%. Seven of the nine dogs achieved excellent outcomes in this study (Preston et al. 1999). The second and more recent study of thirteen dogs using a cementless acetabular component, all thirteen dogs achieved excellent outcomes with a minimum follow-up of 13 months post-surgery (Gifford et al. 2020).

THR in South Africa is still an uncommonly performed procedure. Based on our experience, the majority of owners find the cost of the surgery prohibitive. To our knowledge, a THR on a pelvic limb amputee has only been performed once before in South Africa (personal communication by the author with the veterinarian). Our aim was to report the positive outcome of THR in the management of a traumatic coxo-femoral luxation in a pelvic limb amputee at one year post-surgery. This will hopefully increase awareness in the veterinary community of South Africa for further indications for performing a THR.

Patient presentation

A one-year-old greyhound presented to the Onderstepoort Veterinary Academic Hospital (OVAH) with a history of being involved in a road traffic accident two and a half months prior with bilateral pelvic limb trauma. This trauma consisted of a degloving injury with a fracture of the lateral malleolus of the right tarsus. This resulted in an open tarsal instability with marked soft tissue damage. A cranio-dorsal luxation of the left coxo-femoral joint was present.

The tarsal injury was treated with a type II linear trans-articular external fixator (IMEX Veterinary, Texas, USA). The left coxo-femoral luxation was managed with a toggle rod (Hip toggle 2.5 mm + 250ld Liga fiber and titanium button, Veterinary

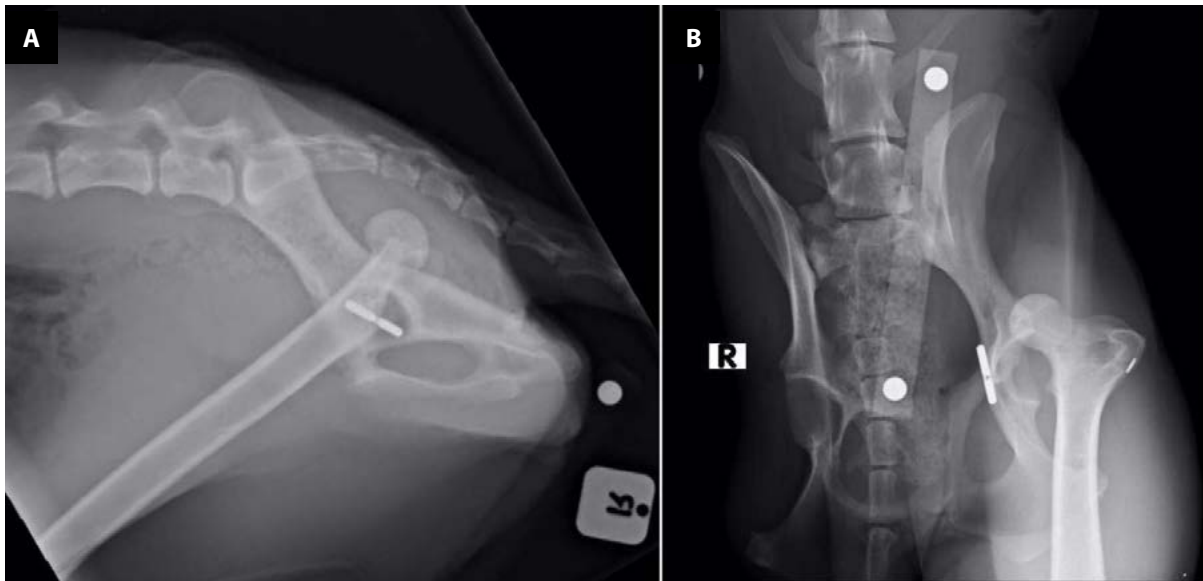


Figure 1: Preoperative ventro-dorsal (A) and lateral (B) radiographs showing a cranio-dorsal hip luxation with a failed toggle rod medial to the acetabulum

Instrumentation, Sheffield, UK) placed after open reduction of the luxation.

The dog was sent home and seen weekly to manage the granulating tarsal wound until further reconstructive surgery could be performed on the wound. During the immediate four weeks post-surgery the owner elected to manage the wound with dressing changes at home and declined returning to the hospital for wound management. The dog developed severe soft tissue complications from the dressing and presented at four weeks post-surgery with vascular compromise distal to the tarsus. The vascular compromise led to avascular necrosis of the distal tarsus and digits.

Given the marked necrosis of the distal tarsus and digits, pelvic limb amputation was advised. At this stage the dog was weight-bearing on the contralateral pelvic limb. Coxo-femoral disarticulation was performed and the dog was discharged weight-bearing on the remaining pelvic limb.

The dog presented with an acute non-weight-bearing lameness on the remaining pelvic limb five weeks after the disarticulation.

Plain film radiography showed cranio-dorsal coxo-femoral luxation with failure of the toggle rod (Figure 1).

A THR or a femoral head and neck resection (FHNR) were discussed as surgical options with the owner. The owner decided, based on the discussions, to proceed with a THR as a definitive treatment option.

The dog was premedicated with Medetomidine (0.01 mg/kg IM, Domitor 1 mg/ml, Zoetis, South Africa) and morphine sulphate (0.3 mg/kg IM, Morphine Sulphate PF, Fresenius Kabi, South Africa) and induced with Propofol to effect (2 mg/kg IV, Propoven 1%, Fresenius Kabi, South Africa). The patient was intubated and placed on Isoflurane (Isofor, Safeline pharmaceuticals, South Africa) and oxygen. A femoral and ischiatic block were performed with Bupivacaine HCL (Macaine HCL 5%, 1 mg/kg SC, Adcock Ingram, Bryanston, South Africa). The entire pelvic limb was aseptically prepared for surgery and a purse string suture

was placed. A cementless total hip system was selected for this dog (Universal hip, BioMedtrix, NJ, USA). This was based on one of the author's familiarity with the system and attendance of the THR course run by BioMedtrix. A standard cranio-lateral approach to the coxo-femoral joint with a partial tenotomy of the deep gluteal tendon of insertion was performed to enable acetabular reaming and femoral broaching. The previous multifilament strands of the toggle rod were identified in the femoral tunnel and removed and sent for culture. Unfortunately it was not possible to retrieve the toggle rod from the medial aspect of the pelvis.

A cementless acetabular cup (BFX, 26 mm cup, Universal hip, BioMedtrix, NJ, USA), a cementless femoral stem (BFX #8 stem, Universal hip, BioMedtrix, NJ, USA) and a femoral head (17+0 mm, Universal hip, BioMedtrix, NJ, USA) were selected based on the preoperative templating on the preoperative radiographs.

A proximal femoral head and neck ostectomy was performed, using the ostectomy guide (BioMedtrix, NJ, USA). This allowed exposure of the acetabulum for acetabular reaming, while maintaining the cancellous envelope of the femoral metaphysis for impaction of the femoral stem.

The acetabulum was sequentially reamed starting with a 18 mm starter reamer (BioMedtrix, NJ, USA) and finally a 26 mm finishing reamer (BioMedtrix, NJ, USA) until the cortical bone of the cis-cortex could be seen. This allows sufficient medialisation of the acetabular cup.

Once the acetabular bed was reamed the femur was broached. This was performed by opening the femoral canal with a 3.2 mm trocar point Steinmann pin (Veterinary Instrumentation, Sheffield, UK) introduced medial to the greater trochanter into the inter-trochanteric fossa. The opening into the femoral canal was then enlarged with a 5 mm drill bit. The femoral canal was then broached, maintaining a 5 degree angle of anteversion starting with a #5 femoral broach (BioMedtrix, NJ, USA), finishing with a #8 femoral broach (BioMedtrix, NJ, USA).

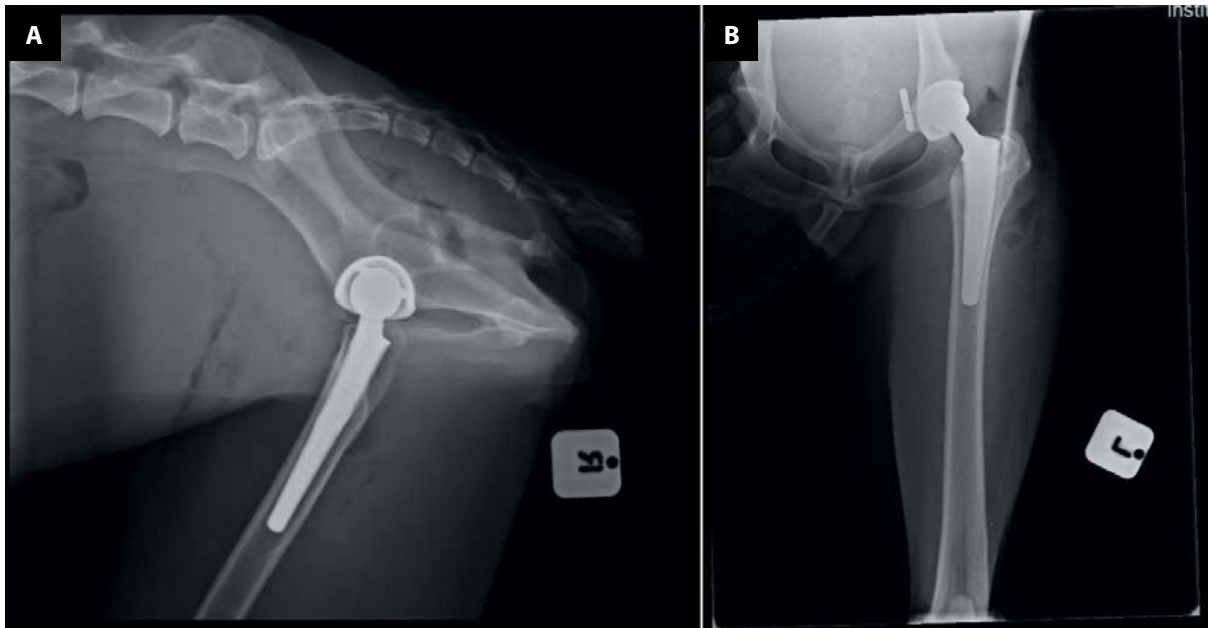


Figure 2: Immediate postoperative radiographs, right lateral (A) and cranio-caudal cross table femur (B) showing implant position

Once the broaching of the femur was complete the acetabulum was exposed for impaction of the acetabular cup. A 26 mm BFX acetabular cup (BioMedtrix, NJ, USA) was impacted to achieve an angle of lateral opening of 45–60°, 15–20° of retroversion and 0° of inclination.

After impaction of the acetabular cup, the femoral canal was exposed and a #8 BFX cementless stem (BioMedtrix, NJ, USA) was impacted in 5° of anteversion.

A 17+0 mm Universal femoral head (BioMedtrix, NJ, USA) was impacted on to the exposed prosthetic neck of the femoral stem. The prosthetic head was reduced into the acetabular component and the range of motion in the implant was assessed for any impingement of the acetabular cup on the neck of the stem.

The surgical site was lavaged and closed in a routine manner.

Postoperative radiographs were taken prior to the patient recovering from anaesthesia to assess implant placement and angulation of the implants relative to each other (Figure 2). The postoperative position of the radiographs showed an angle of lateral opening of the acetabular cup of 45°, 2–3° of inclination and 15° of retroversion. The femoral stem was positioned with 2–3° of anteversion and mild cranial caudal tilting in the femoral canal.

Management and outcome

The dog was supported with sling walking in the ICU unit for the first three days post-surgery and was ambulatory on the pelvic

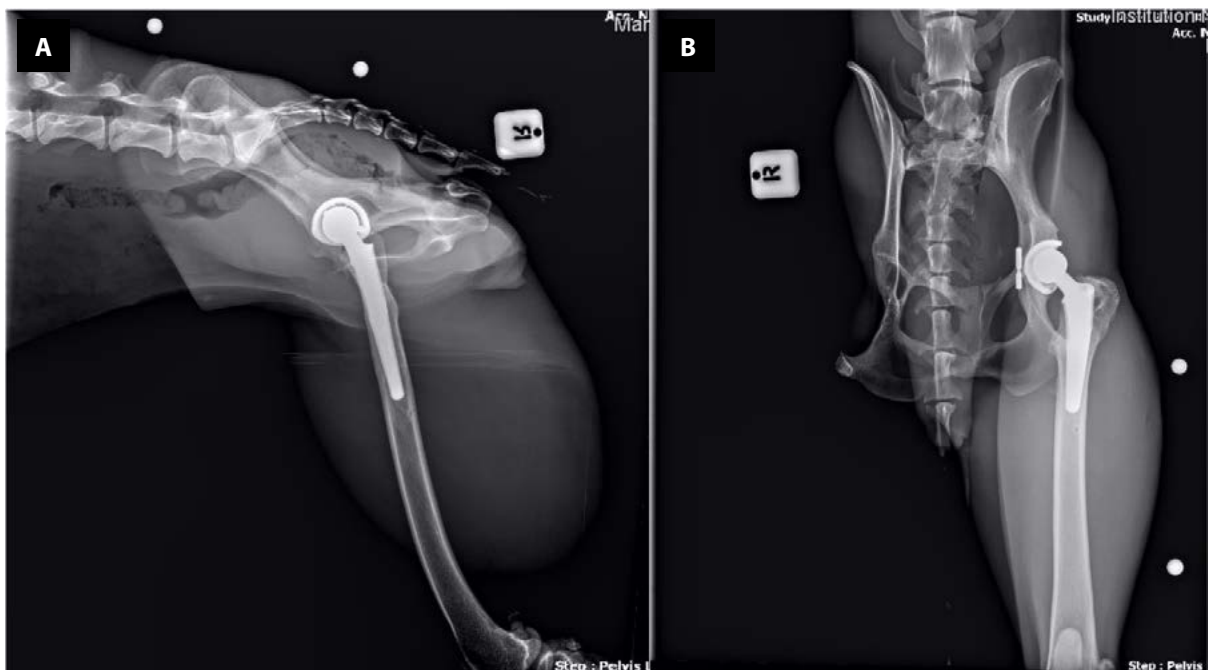


Figure 3: Follow-up lateral (A) and (B) ventro-dorsal radiographs taken 12 months post-surgery showing osseous integration with the implants

limb. On day four post-surgery the dog was ambulatory on the limb and did not require further sling walking. The dog was cage rested at the OVAH for three weeks post-surgery. The dog received daily physiotherapy and rehabilitation as set out by the certified rehabilitation practitioner at the OVAH. The owner was instructed to crate rest the dog for another three weeks at home and return for follow-up radiographs four weeks' post-surgery. The owner did not return for radiographs but a telephonic follow-up was performed at six weeks after the surgery. The owner reported that the dog was walking on the leg with no pain or discomfort. The dog returned for follow-up radiographs three months after the surgery at the request of the authors. The follow-up radiographs showed early osseous integration into the implants with limited subsidence. A full orthopaedic exam was performed by the authors three months post-surgery on the dog. The results of this exam were felt to be within normal limits for a pelvic limb amputee. A repeat telephonic follow-up was performed 11 months post-surgery and the owners were requested to return at a year post-surgery for follow-up radiographs.

Follow-up radiographs taken 12 months post-surgery showed complete osseous integration of the implants with no radiographic signs of infection or aseptic loosening of the implants. A repeat orthopaedic exam was found to be similar to the orthopaedic exam performed at three months post-surgery.

Discussion

This case report details a single case of a successful THR for management of a traumatic coxo-femoral luxation using a cementless system in a pelvic limb amputee.

In many countries around the world THR surgeries are regularly performed in specialist practice with excellent outcomes (Forster et al. 2012). In South Africa the cost of a THR limits the use of the procedure even in specialist practice. As there are few clients who can afford THR surgery, there are fewer veterinarians who have clinical expertise and experience in performing THR surgery. Our THR programme at the OVAH is still in its infancy, and the effect of inexperienced surgeons performing THR surgery is associated with a higher postoperative complication rate (Hayes et al. 2011).

The most commonly seen complications following THR can be grouped into early postoperative < 12 weeks and delayed postoperative complications > 12 weeks after surgery. The majority of complications occur in the early postoperative period, the most common being luxation of the femoral head, femoral fracture, ischiatic neuropraxia and surgical site infection (Dyce et al. 2000; Forster et al. 2012; Hayes et al. 2011). The most common complications seen in the long-term postoperative period are aseptic loosening and delayed surgical site infections (Dyce et al. 2000; Forster et al. 2012).

THR has been reported in pelvic limb amputees before, with a higher rate of femoral head luxation with the use of cemented versus cementless acetabular cup (Gifford et al. 2020; Preston et al. 1999). In performing revision surgery on the femoral head luxation in the study looking at cemented acetabular cups, the angle of lateral opening was further closed to prevent luxation (Preston et al. 1999). The more recent study using a cemented

acetabular cup showed outcomes comparable to THR in dogs that were not pelvic limb amputees. This study found that it was not necessary to close the cup more than recommended to prevent luxation. They proposed that the rigid metal backing of the cementless acetabular cup provided greater resistance to luxation compared to the cementless polyethylene cup (Gifford et al. 2020).

A FHNR is an alternative surgical procedure to manage a recurrent coxo-femoral luxation, a coxo-femoral luxation with secondary osteoarthritis or damage to the articular surface or coxo-femoral joint trauma (Denny 1978; Matis 2010; Moores 2006). Unfortunately the majority of studies looking at the outcomes of FHNR are older and based on subjective evaluation measures, mainly owner satisfaction (Matis 2010). Kinematic gait analysis has been used on a subseries of one study population and this showed that although a FHNR alleviated pain, only 38% of the dogs assessed had a satisfactory gait analysis (Matis 2010). In the dog in this study the concern was that the gait alterations caused by being a pelvic limb amputee (Contreras et al. 2018) would affect the outcome if a FHNR was performed. This may have led to decreased owner satisfaction with the procedure.

Based on the successful outcomes seen with the use of a cementless acetabular cup in pelvic limb amputees, we elected to use a cementless acetabular cup in the surgical procedure in this dog (Gifford et al. 2020).

The owner of the dog was made aware of our lack of experience with THR surgery and that this has been associated with higher postoperative complication rates (Hayes et al. 2011). Given our lack of experience with the procedure, only having performed 38 THRs in our institution at the time of this case, there were concerns about how a major postoperative complication would affect this dog, being a pelvic limb amputee. Thankfully there were no patient factors present such as a medialised trochanter, luxoid deformity, lower canal flare index or severe secondary osteoarthritis with a dish shaped acetabulum that would have made the THR more challenging (Ganz et al. 2010).

The limitations of this report are similar to many case reports where the sample size of a single patient will not allow any relevant long-term conclusions to be drawn. The owner satisfaction in this single case was excellent. Unfortunately we were only able to assess the outcome with owner evaluations and veterinary examinations of the dog. There are no facilities to perform a kinematic gait assessment nor force plate analysis at our institution. We are not able to conclusively state that this patient would not have had a successful outcome had a FHNR been performed.

However, the successful surgical outcome and 12-month follow up in this case shows that THR is a surgical option that should be considered in cases of recurrent traumatic coxo-femoral luxation even if the dog is a pelvic limb amputee.

Ethical approval

Ethical approval was obtained from the University of Pretoria Faculty of Veterinary Science Research Ethics Committee REC139-22.

ORCID

RC Elliot  <https://orcid.org/0000-0001-8051-5706>KJ van der Wettersing  <https://orcid.org/0000-0002-3902-2739>A Kitshoff  <https://orcid.org/0000-0001-9657-740X>

References

- Contreras, E.T., Worley, D.R., Palmer, R.H., et al., 2018, Postamputation orthopedic surgery in canine amputees: Owner satisfaction and outcome, *Topics in Companion Animal Medicine* 33(3), 89-96. <https://doi.org/10.1053/j.tcam.2018.07.001>.
- Denny, H.R., 1978, Pelvic fractures in the dog: a review of 123 cases, *Journal of Small Animal Practice* 19(1-12), 151-166. <https://doi.org/10.1111/j.1748-5827.1978.tb05470.x>.
- Dyce, J., Wisner, E.R., Wang, Q., et al., 2000, Evaluation of risk factors for luxation after total hip replacement in dogs, *Veterinary Surgery* 29 (6), 524-532. <https://doi.org/10.1053/jvet.2000.17858>
- Forster, K.E., Wills, A., Torrington, A.M., et al., 2012, Complications and owner assessment of canine total hip replacement: A multicenter internet based survey, *Veterinary Surgery* 41(5), 545-550. <https://doi.org/10.1111/j.1532-950X.2012.01015.x>.
- Ganz, S.M., Jackson, J., VanEnkevort, B., 2010, Risk factors for femoral fracture after canine press-fit cementless total hip arthroplasty, *Veterinary Surgery* 39(6), 688-695. <https://doi.org/10.1111/j.1532-950X.2010.00694.x>.
- Gifford, A.B., Lotsikas, P.J., Liska, W.D., et al., 2020, Total hip replacement in dogs with contralateral pelvic limb amputation: A retrospective evaluation of 13 cases, *Veterinary Surgery* 49(8), 1487-1496. <https://doi.org/10.1111/vsu.13513>.
- Hayes, G.M., Ramirez, J., Hobbs, S.J.L., 2011, Use of the cumulative summation technique to quantitatively assess a surgical learning curve: canine total hip replacement, *Veterinary Surgery* 40(1), 1-5. <https://doi.org/10.1111/j.1532-950X.2010.00752.x>.
- Jones, S.C., Bula, E., Dyce, J., 2019, Total hip arthroplasty to address chronic hip luxation with pseudoacetabulum formation in seven dogs, *Veterinary Surgery* 48(8), 1530-1539. <https://doi.org/10.1111/vsu.13317>.
- Kalis, R.H., Liska, W.D., Jankovits, D.A., 2012, Total hip replacement as a treatment option for capital physeal fractures in dogs and cats, *Veterinary Surgery* 41(1), 148-155. <https://doi.org/10.1111/j.1532-950X.2011.00919.x>.
- Liska, W.D., 2010, Micro total hip replacement for dogs and cats: surgical technique and outcomes, *Veterinary Surgery* 39(7), 797-810. <https://doi.org/10.1111/j.1532-950X.2010.00725.x>.
- Marino, D.J., Ireifej, S.J., Loughin, C.A., 2012, Micro total hip replacement in dogs and cats, *Veterinary Surgery* 41(1), 121-129. <https://doi.org/10.1111/j.1532-950X.2011.00933.x>.
- Matis, U., 2010, Excision arthroplasty of the hip joint in dogs and cats, *Veterinary and Comparative Orthopaedics and Traumatology* 23(05), 297-305. <https://doi.org/10.1055/s-0037-1617478>.
- Moore, A., 2006, Decision making in the management of hip luxations in dogs and cats, *In Practice* 28(10), 570. <https://doi.org/10.1136/inpract.28.10.570>.
- Preston, C.A., Schulz, K.S., Vasseur, P.B., 1999, Total hip arthroplasty in nine canine hind limb amputees: a retrospective study, *Veterinary Surgery* 28(5), 341-347. <https://doi.org/10.1111/j.1532-950X.1999.00341.x>.